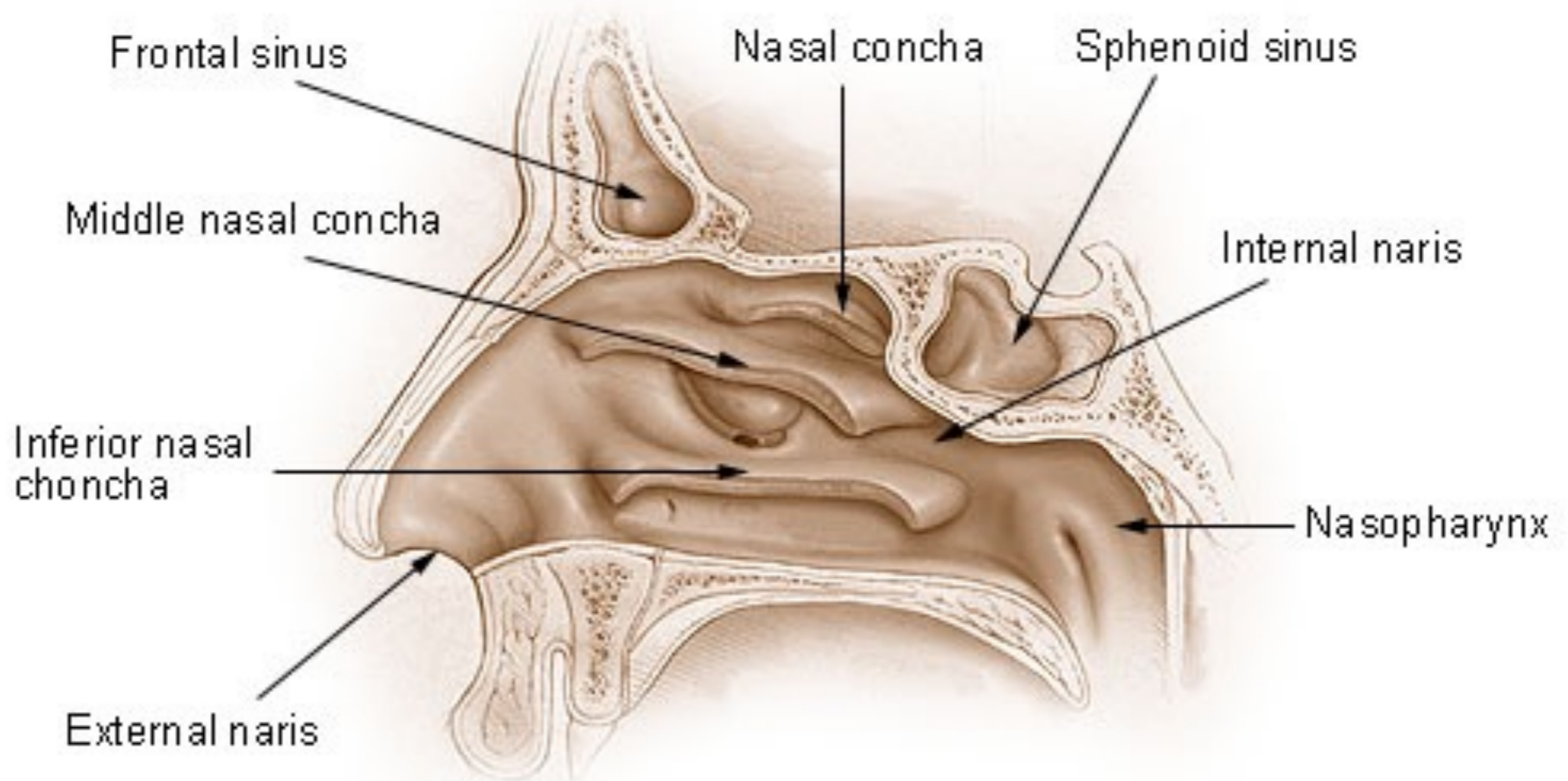


# Inferior turbinate hypertrophy



*Mohammed Saad Alobayli*  
*Intern*

## Nose and Nasal Cavities



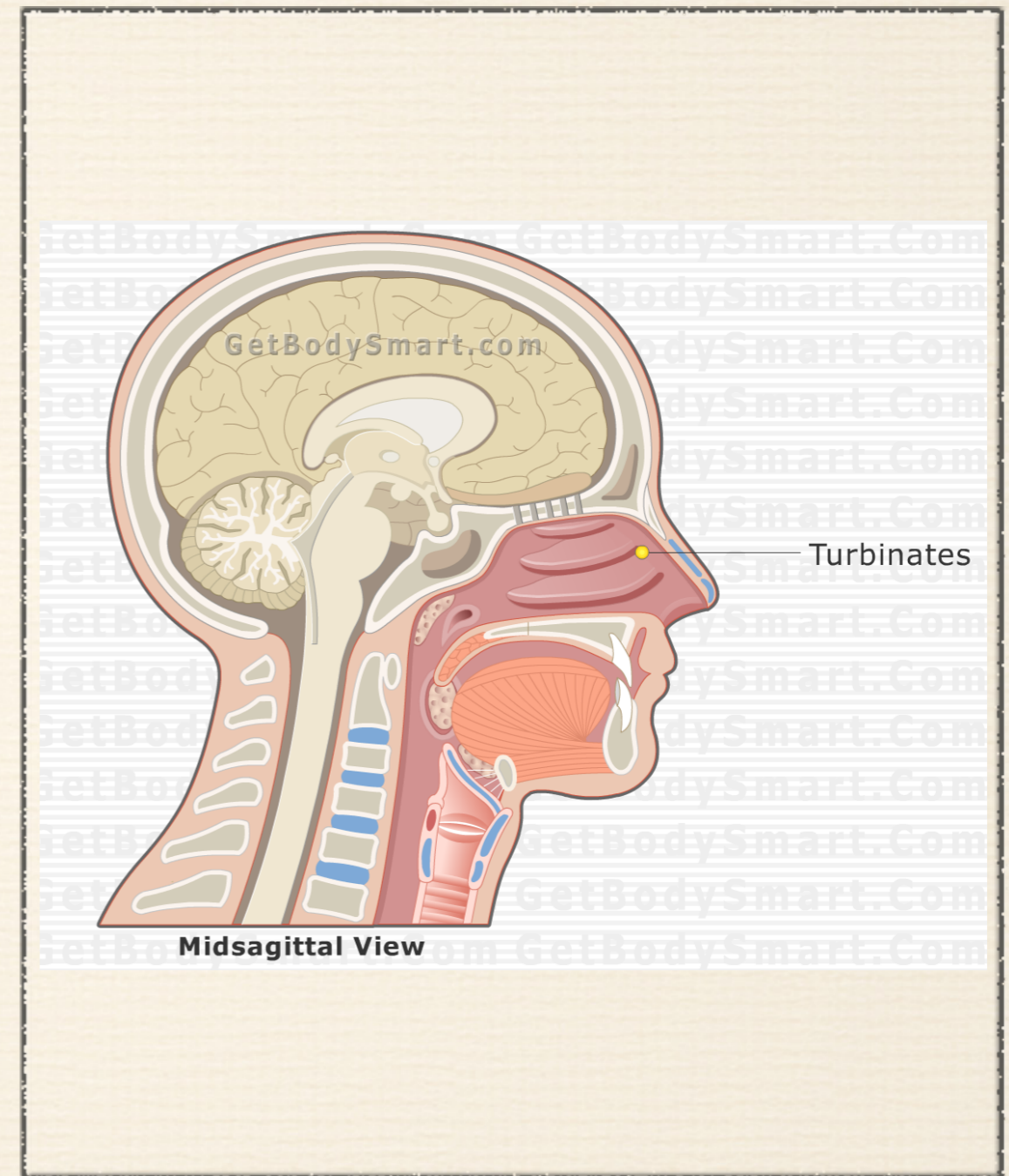
# Anatomy

Turbinates are consist of :

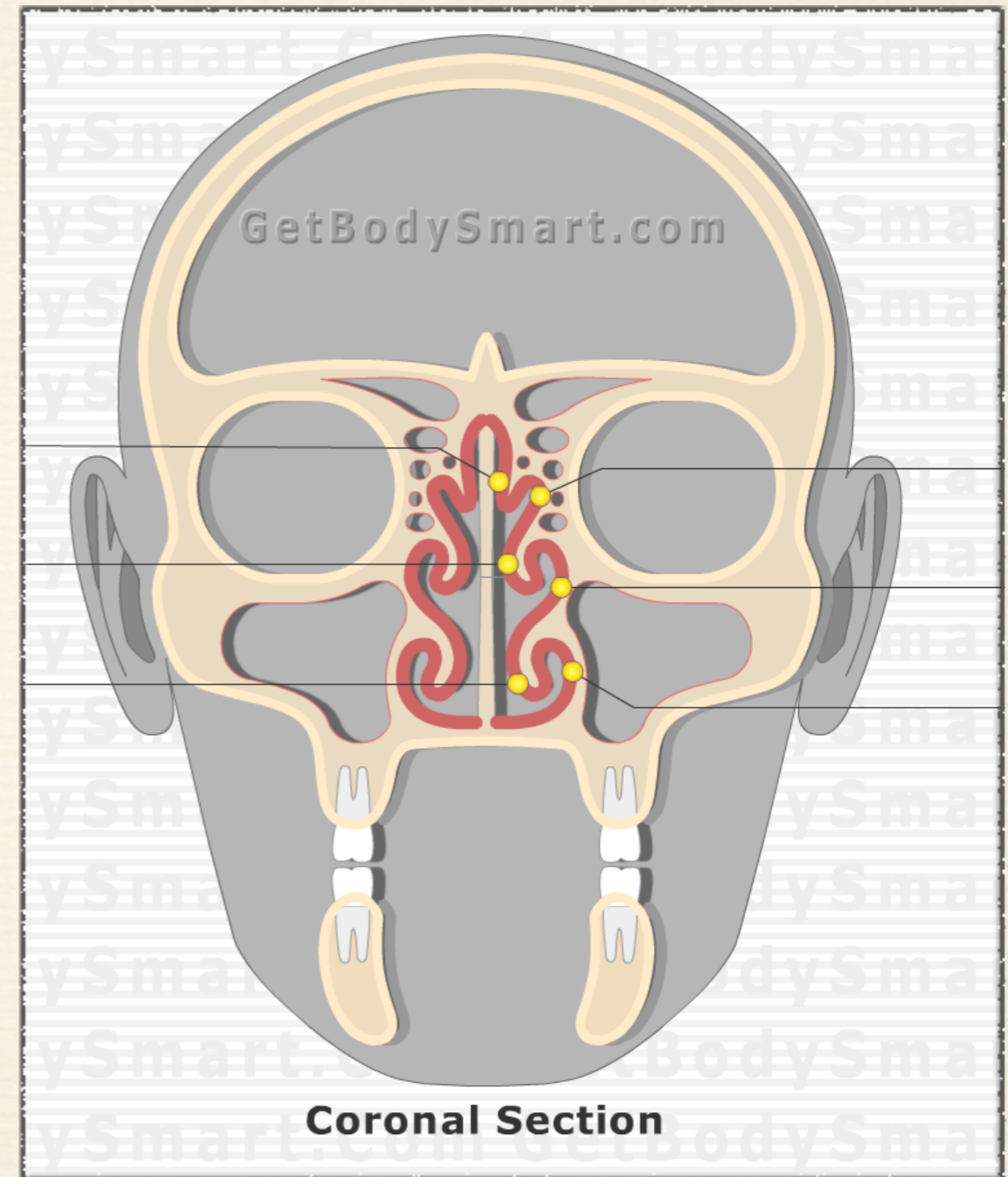
1- Superior turbinates- ethmoid bone

2- Middle turbinates -ethmoid bone

3- Inferior turbinates - maxilla bone



- Grooves called meatuses are found between the curved turbinate.
- The turbinates divide the nasal airway into four groove-like air passages.
- The inferior turbinates are the largest turbinates. and can be as long as the index finger in humans.



- Blood supply to the nose comes from branches of both the internal and external carotid artery systems
- Autonomic nervous provides the general innervation to the nose with the parasympathetic nerves

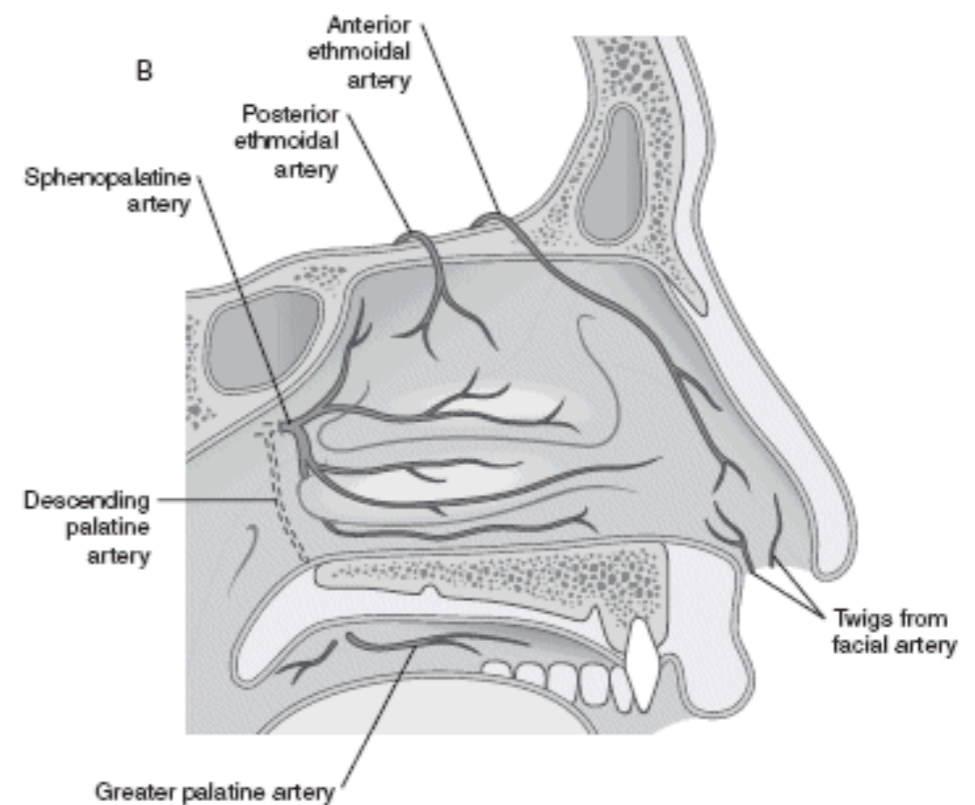
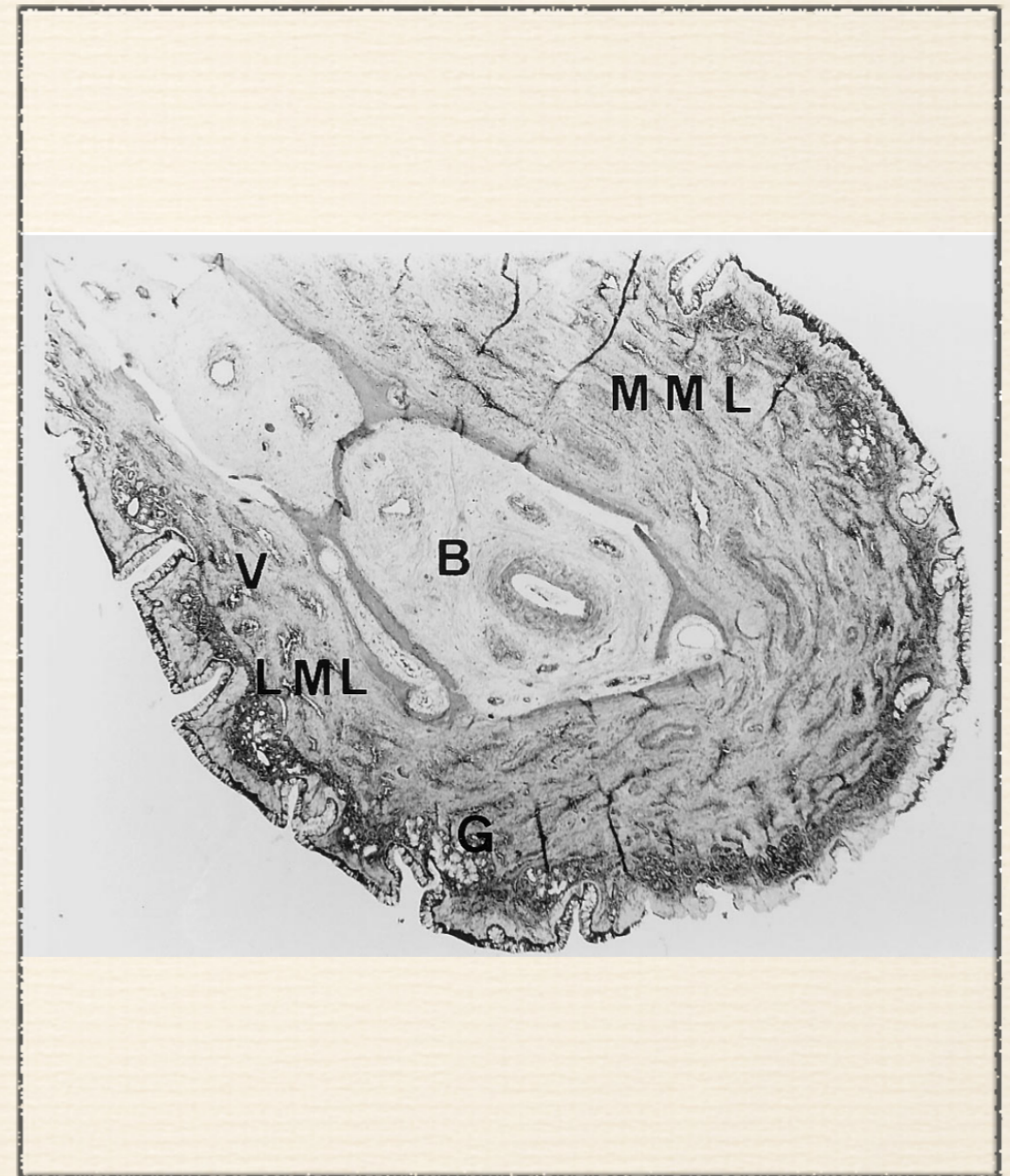


Figure 47-1b. Arterial supply to the nose.

# Histology

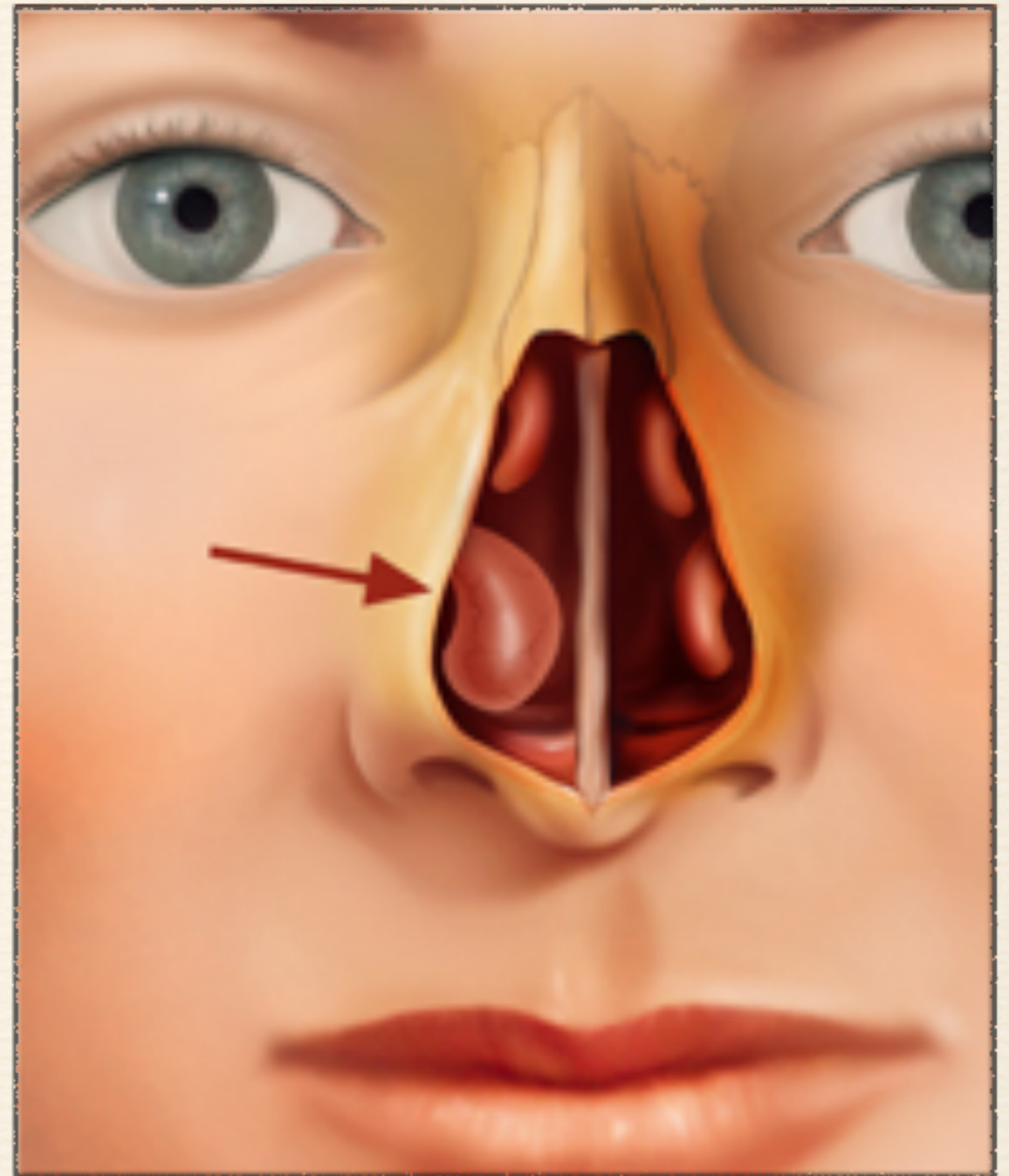
The inferior turbinate is composed of three layers:

- Medial mucosal layers
- Lateral mucosal layers
- Central osseous
- ❖ Covered with a pseudo-stratified columnar epithelium.
- ❖ Goblet cells
- ❖ Venous sinusoids



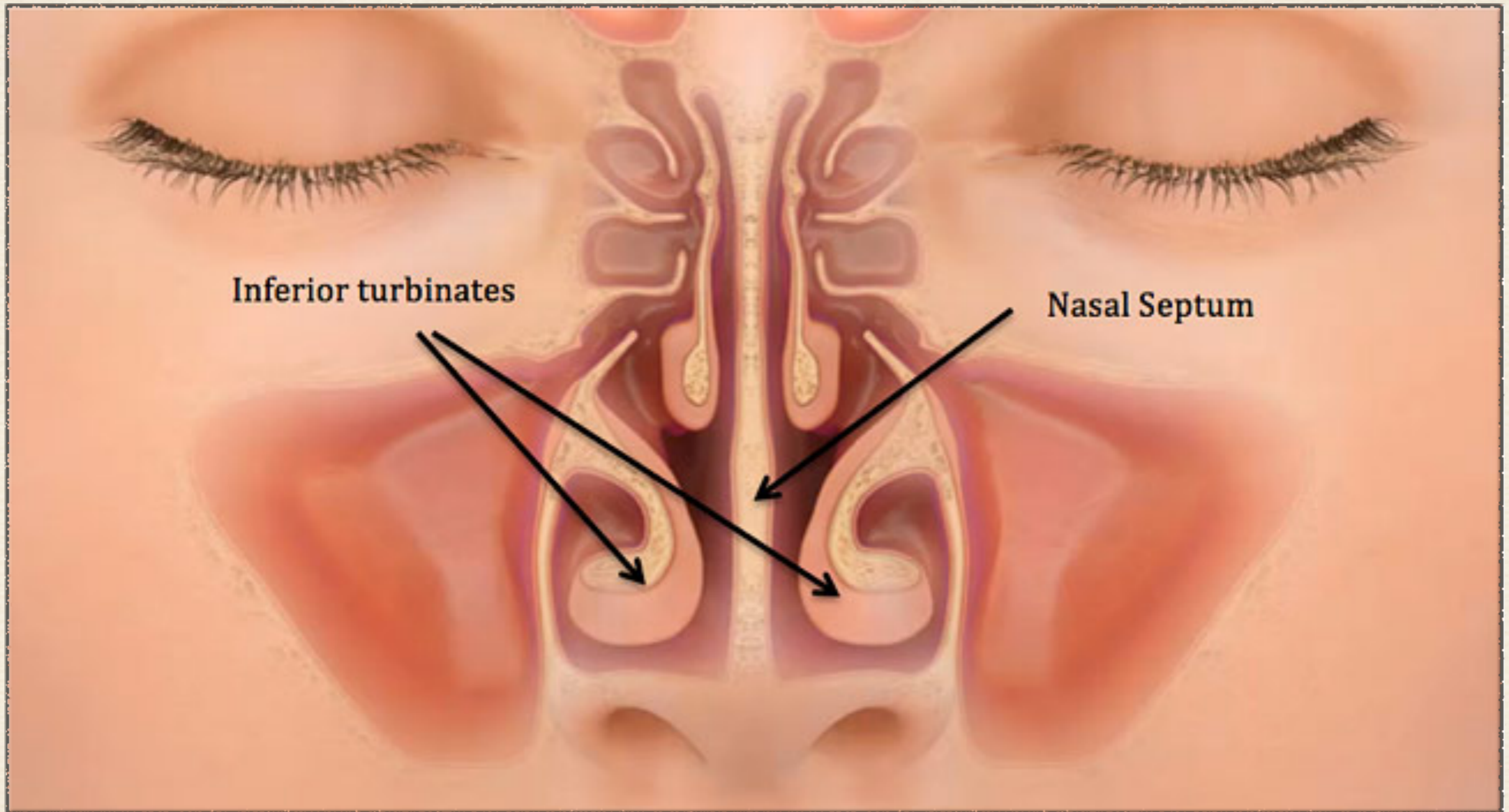
# Physiology

- The turbinates are enriched with airflow pressure and temperature-sensing nerve receptors.
- Pterygopalatine ganglion.
- Immunological defense
- Serves as a filter

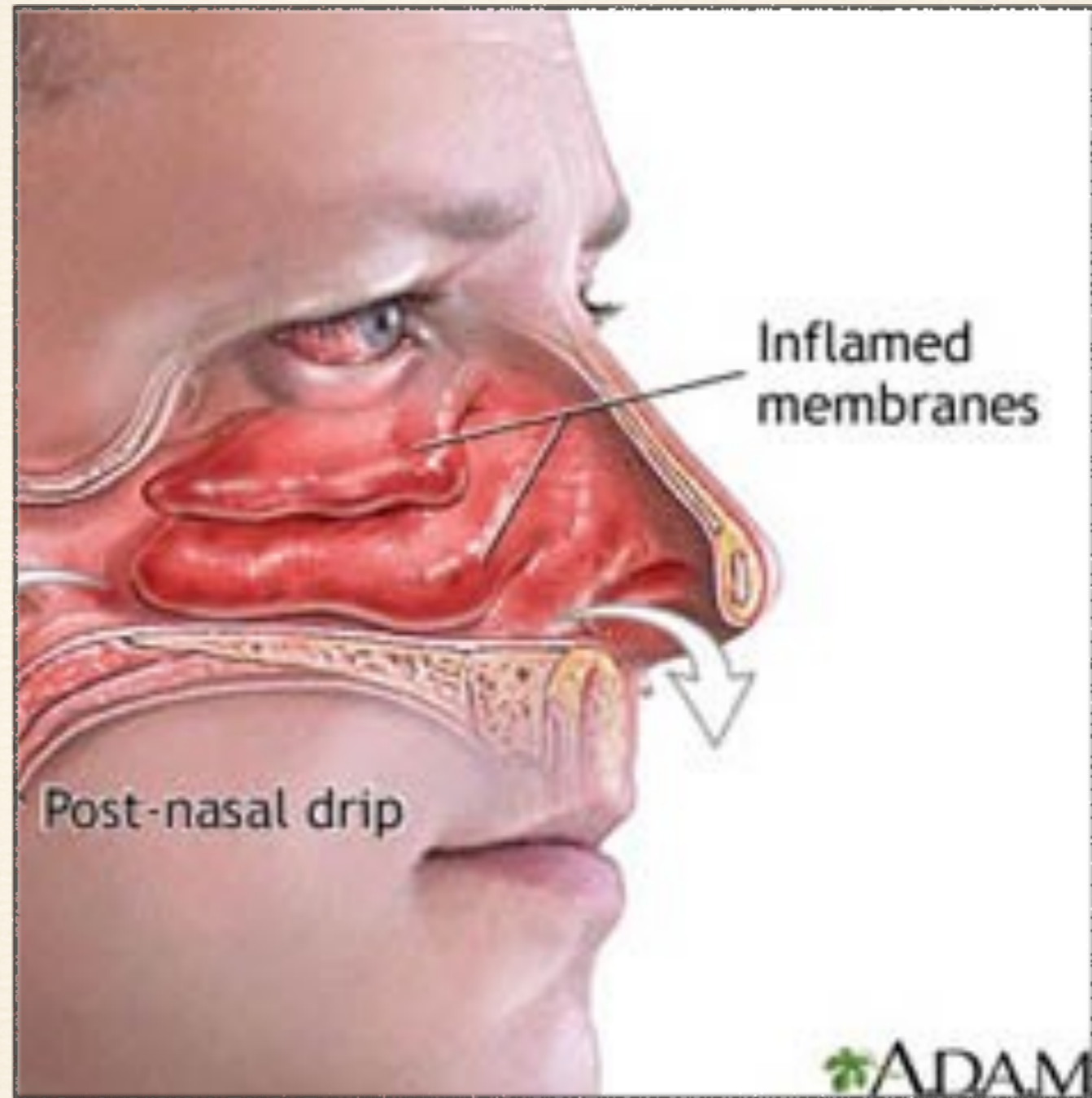




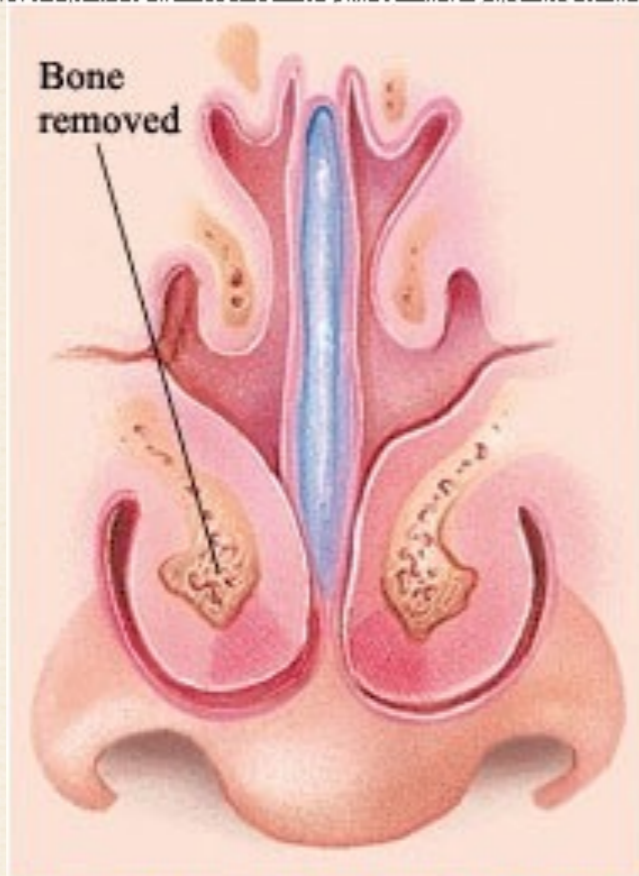
# Causes



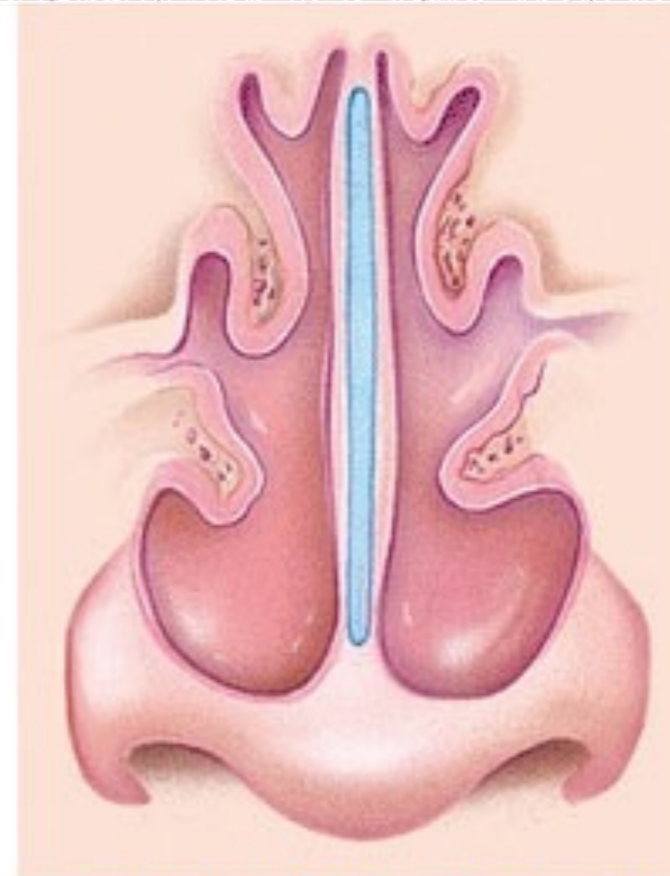
- Allergies.
- Vasomotor rhinitis.
- Medications.
- Hormonal.
- Rhinitis of disuse.



# Management



**During surgery, bone or mucous membrane may be removed from enlarged turbinates.**



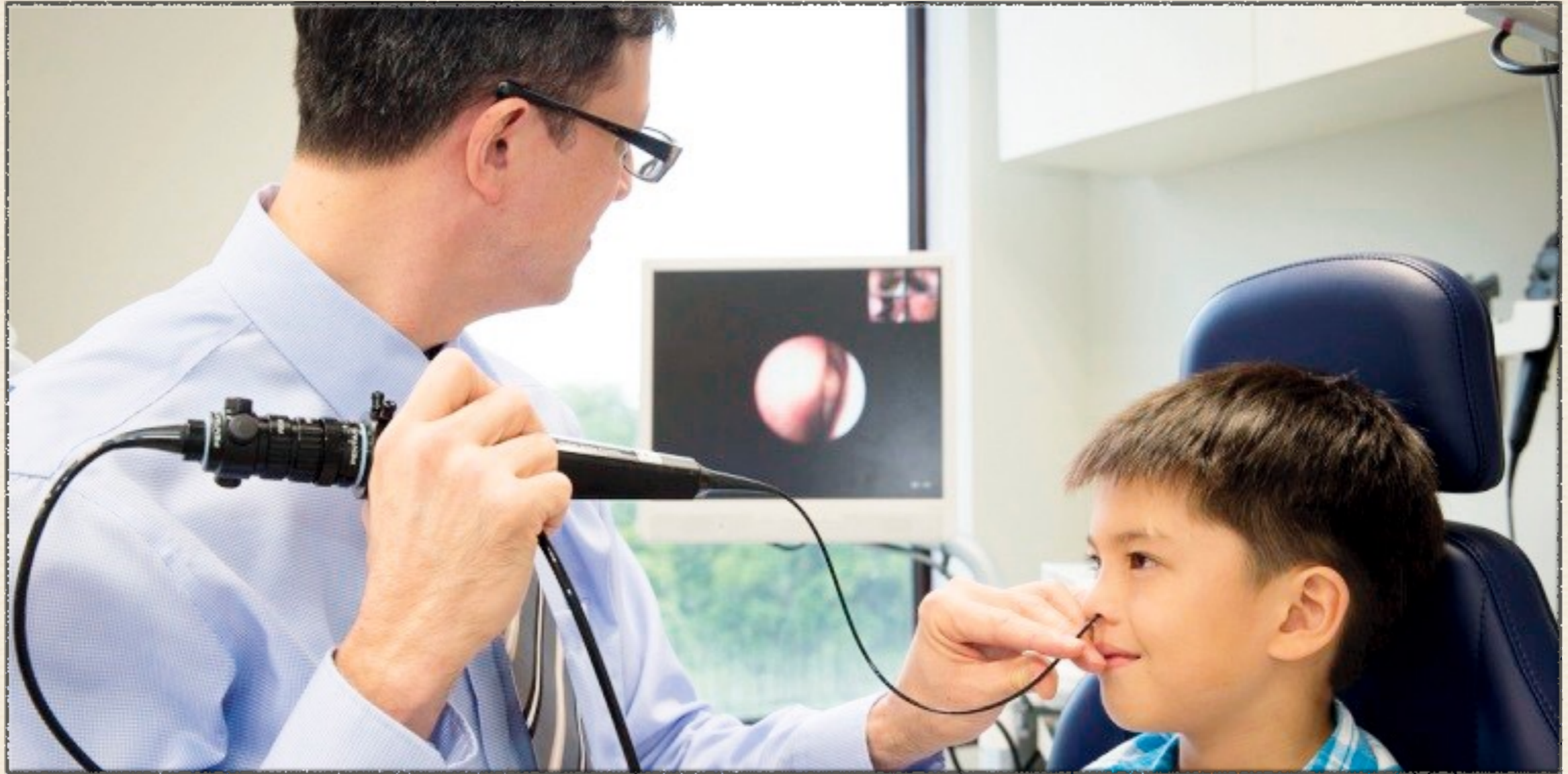**After surgery, there is more breathing space. Enough turbinate bone and mucous membrane remain for the turbinates to do their job.**

# History

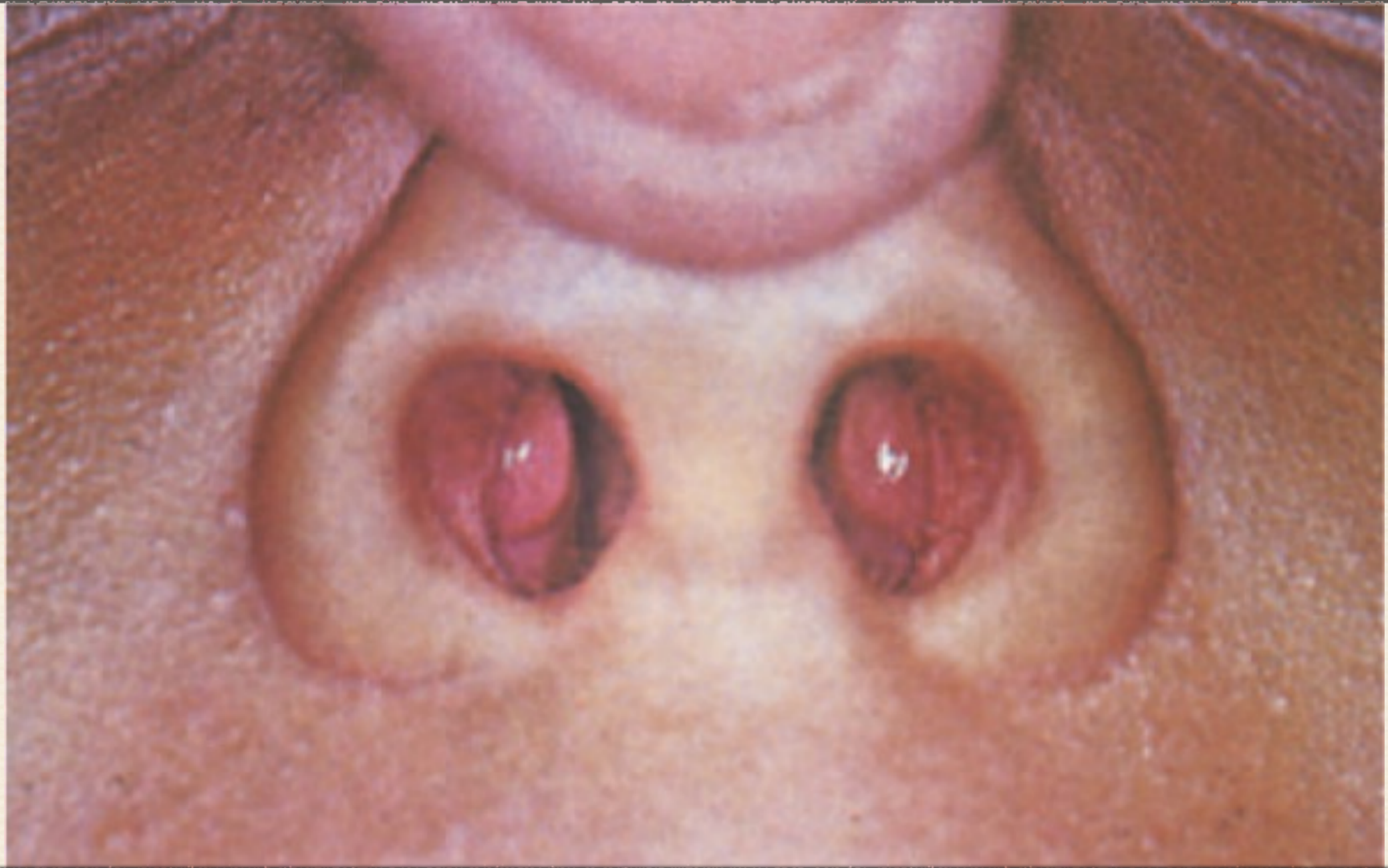
- A patient's history plays an invaluable role.
- Severity.
- Frequency.
- Duration.
- Exacerbating factors.
- Before and after topical decongestion is conducted.



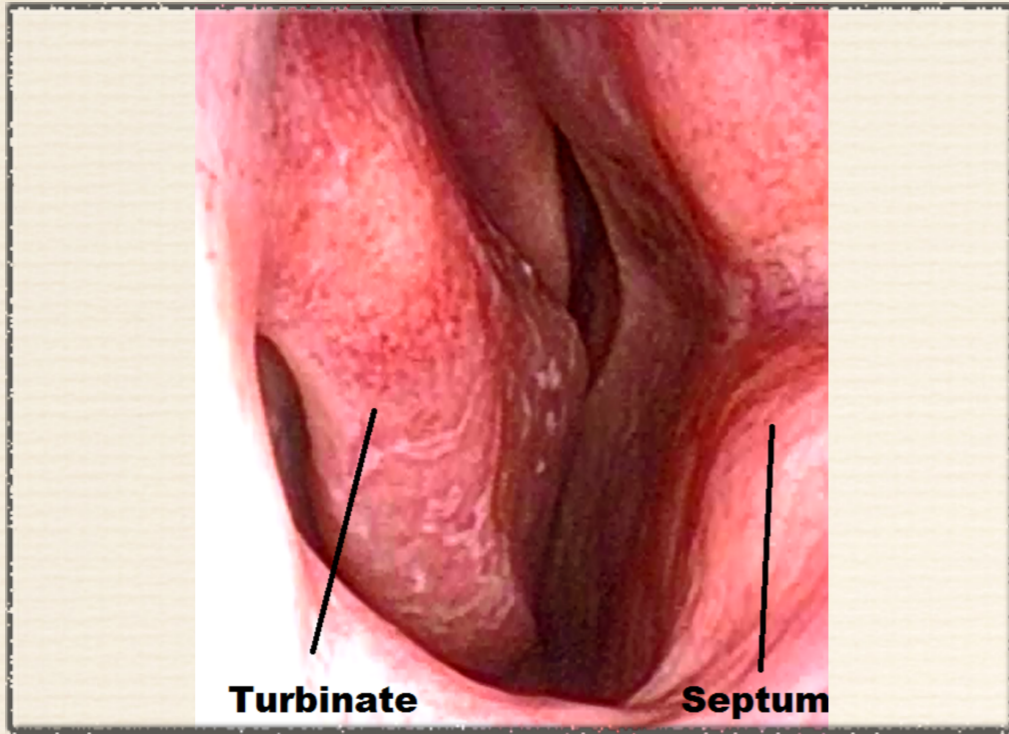
# Examination



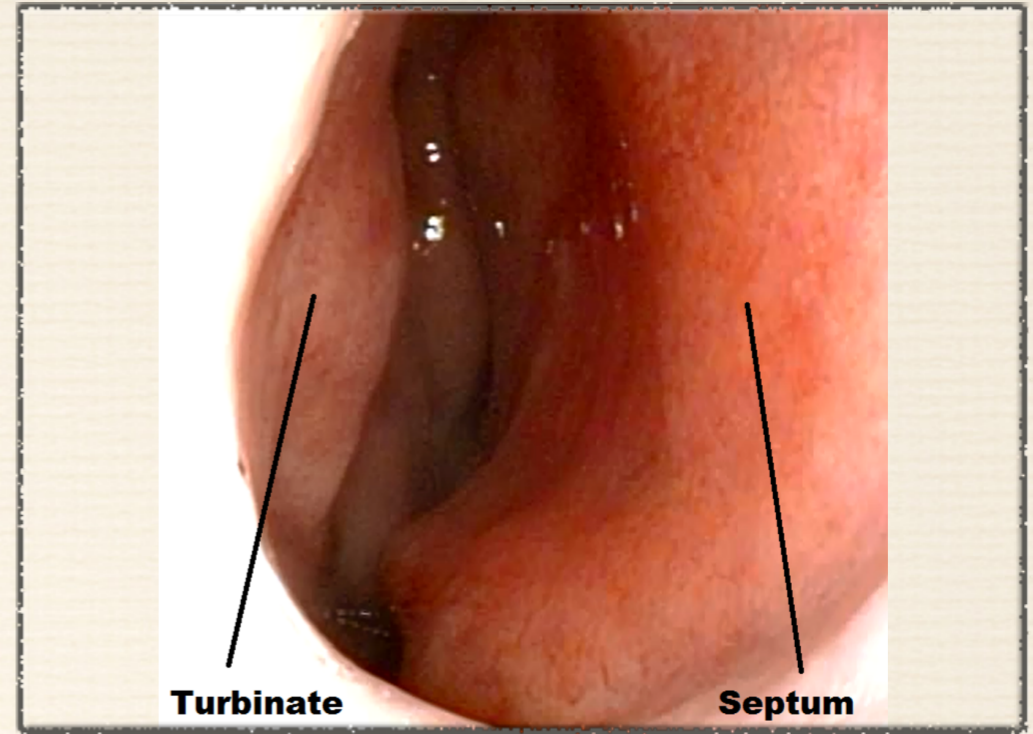
- Rule out other obstructive lesions.
- Septal deviations, mucosal inflammation, purulence, or polyps.
- Evaluation of the nasopharynx.



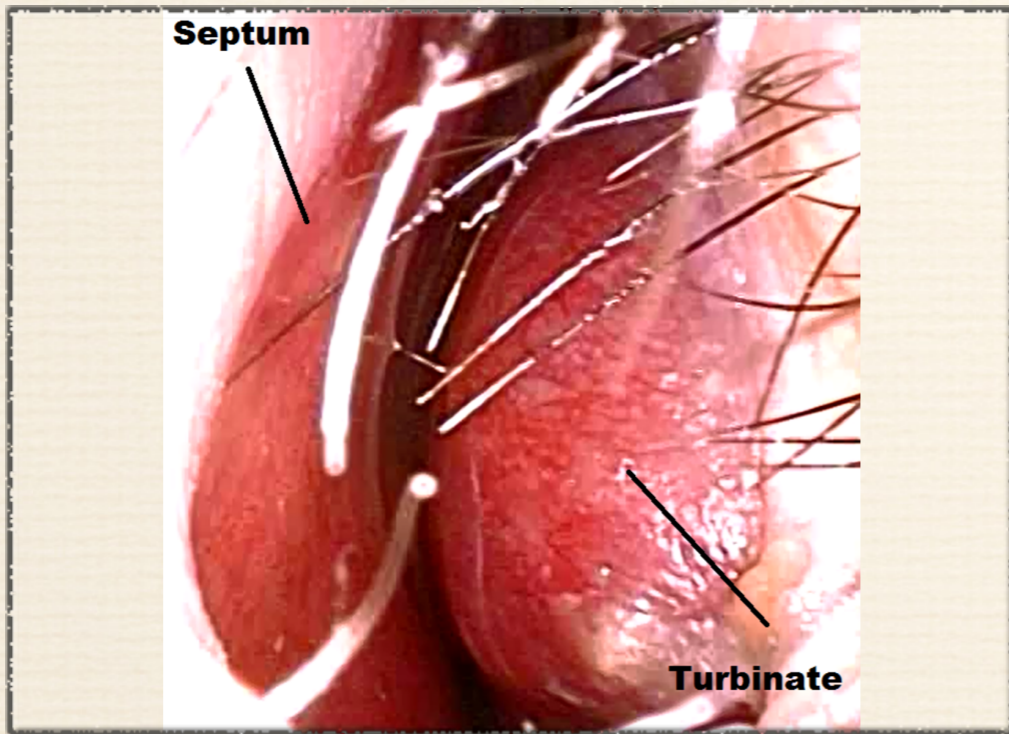
- Grade 1 is 0-25% of the airway.
- Grade 2 is 26-50% of the airway
- Grade 3 is 51-75% of the airway
- Grade 4 is 76-100% of the airway.



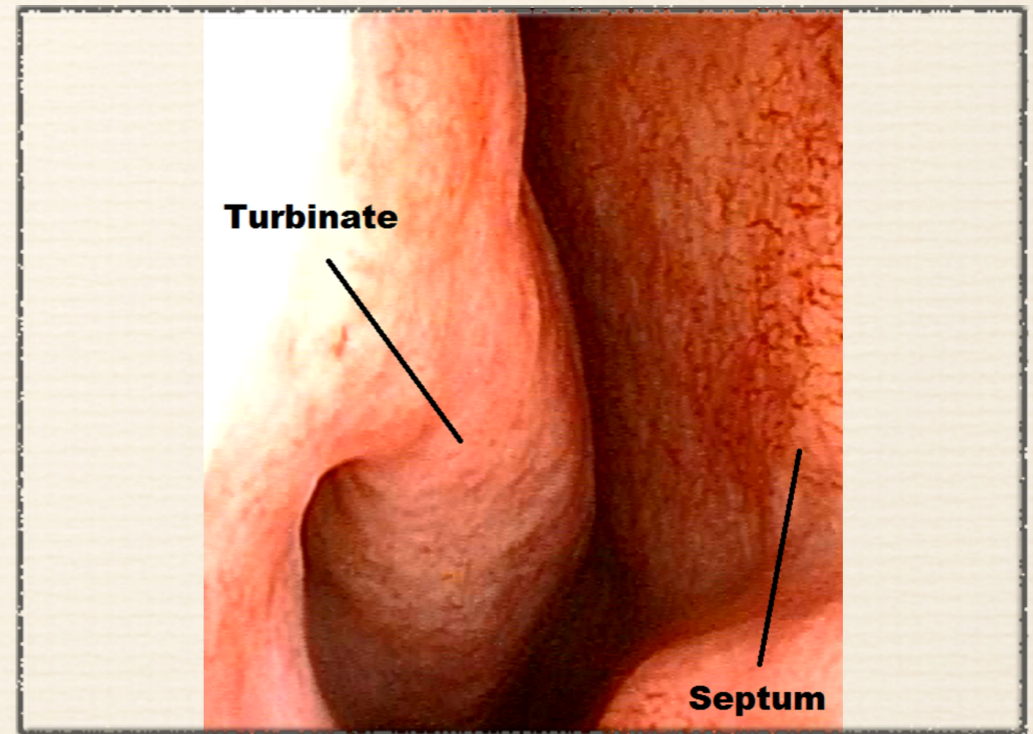
Grade 2 inferior turbinate



Grade 1 inferior turbinate

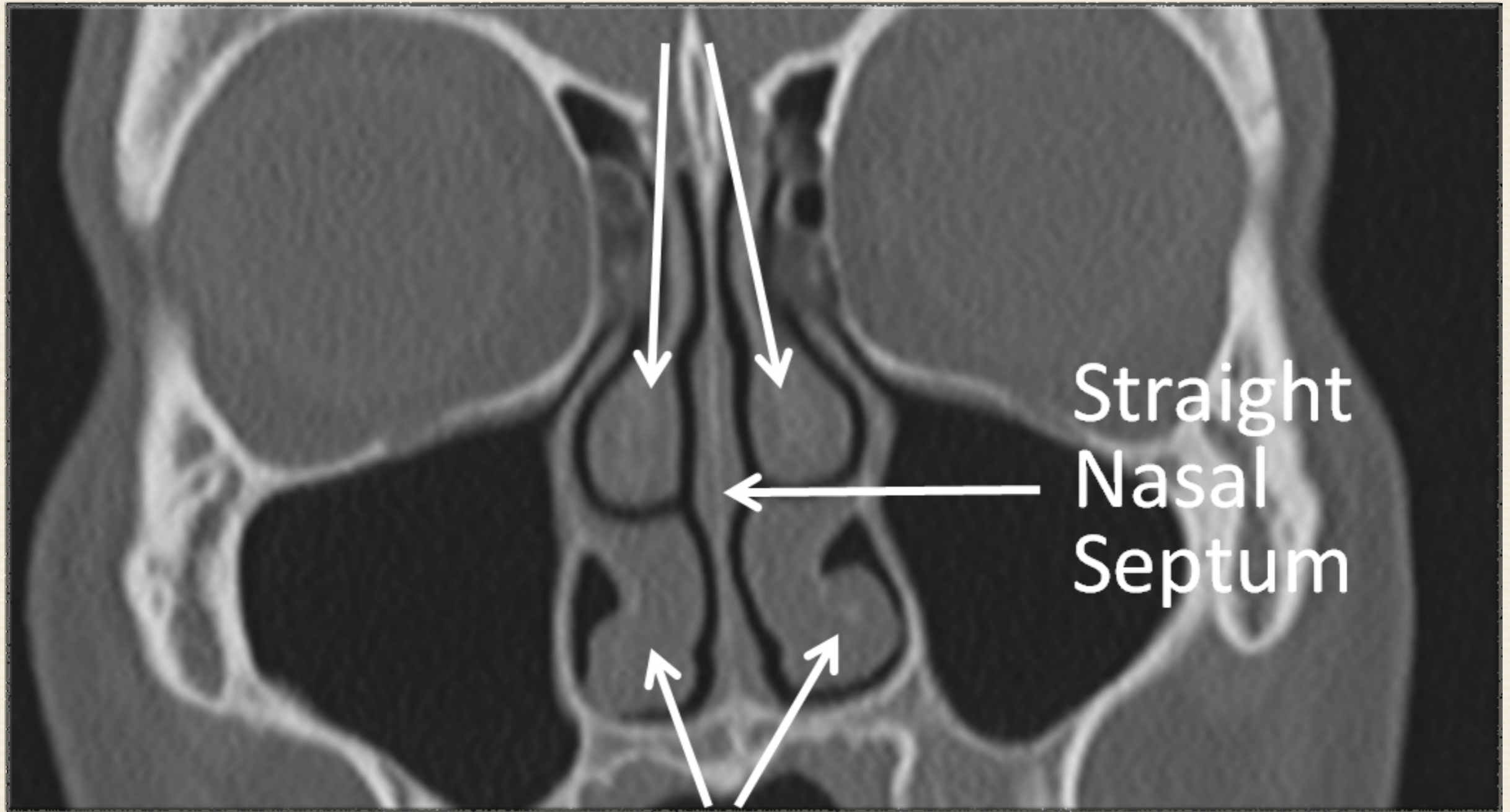


Grade 4 inferior turbinate



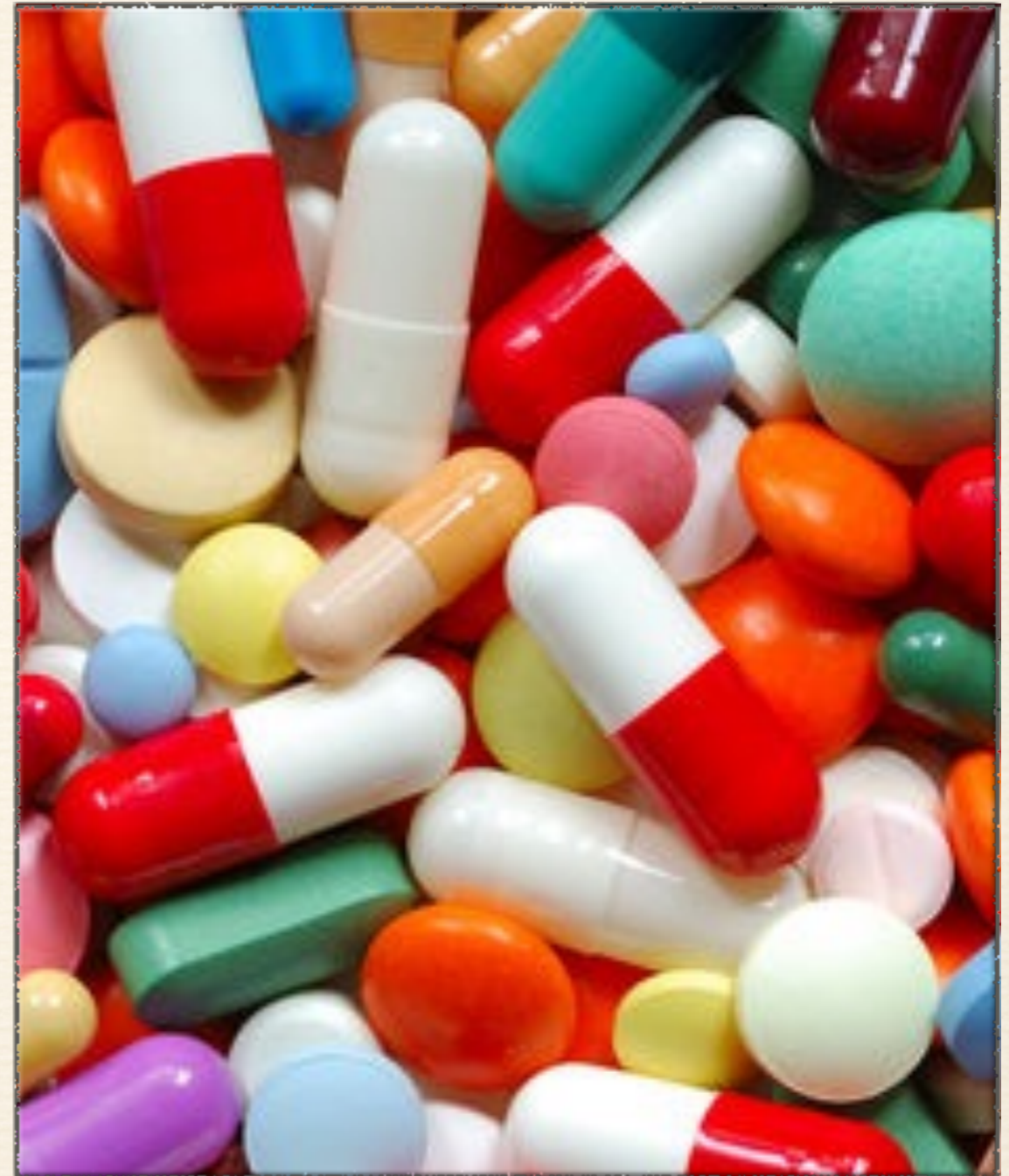Grade 3 inferior turbinate

# Imaging



# Medical Therapy

- Medical therapy is the first-line approach to the treatment of turbinate dysfunction.
- Nasal decongestants:
  1. Topical sprays, Oxymetazoline and phenylephrine.
  2. Oral decongestants, Pseudoephedrine and phenylephrine.
- Antihistamines.
- Intranasal steroid sprays.
- Leukotriene receptor antagonist montelukast
- Intraturbinate injections of steroids

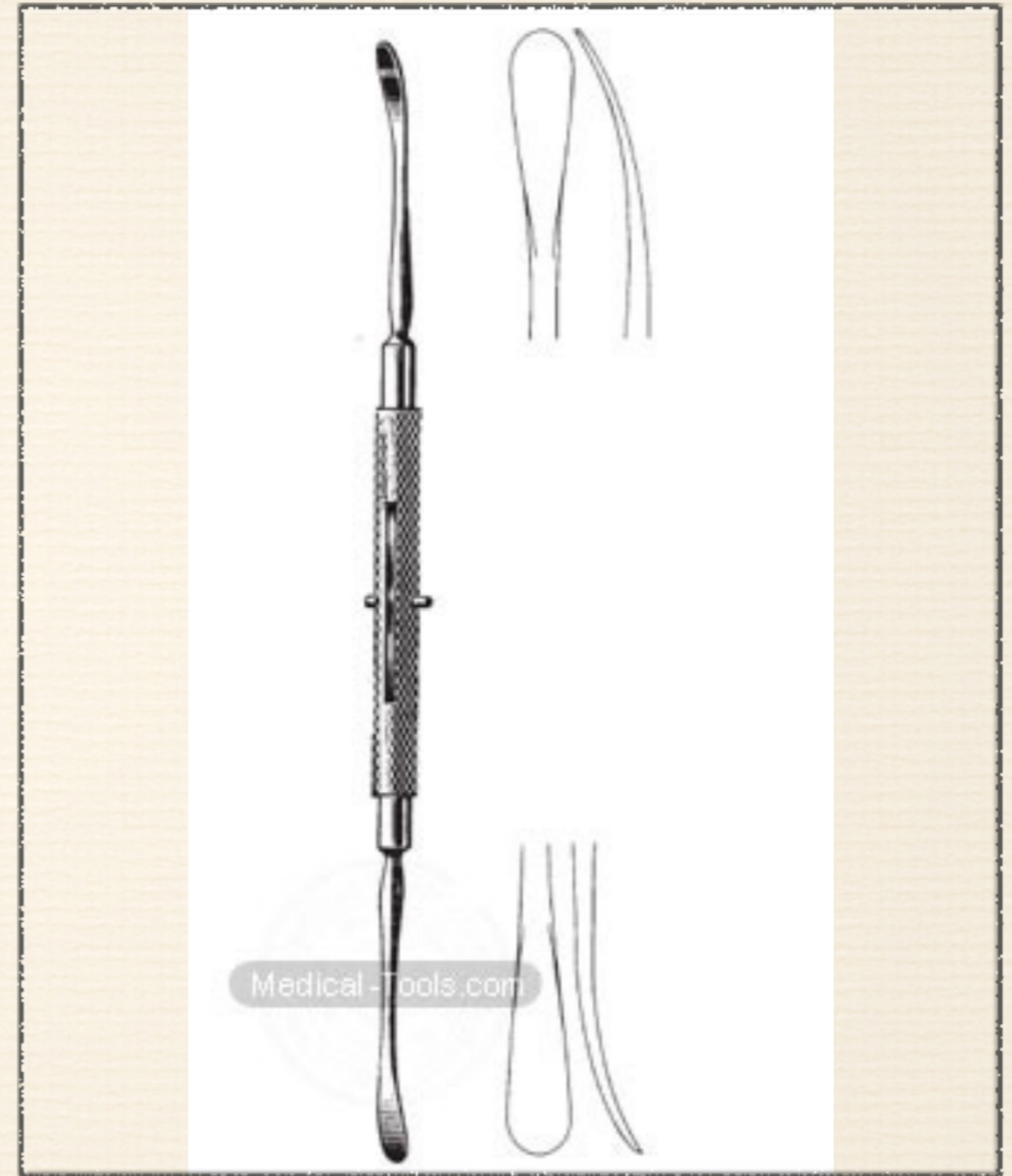


# Surgical Therapy

- Surgical therapy is reserved for symptomatic patients with persistent hypertrophy of the turbinates who are not responding to medical management or in whom medical management is contraindicated.
- Surgical management can target both the bony and the mucosal components. Numerous techniques and variations have been developed.
- IT surgery can be performed in an office setting or may be done in the operating room
- Considerations for technique selection.
- The techniques have changed in frequency of use over the past 40 years.
- Partial and total turbinectomy waned significantly.
- Contemporary literature.

# TURBINATE OUTFRACTURE

- Lateral repositioning of the inferior turbinates via out-fracturing
- Modest improvement in nasal airway.
- Goldman/Boise elevator and Freer elevator.
- Obvious limitation.
- Statistically significant degree of lateralization



# EXTRAMURAL RESECTION

- Total inferior turbinates resection has been used for many years.
- This is the most aggressive turbinate procedure.
- Objective criteria for a widely patent airway are certainly obtained.
- Empty nose syndrome.
- Total IT resection has largely fallen out of favor.
- Partial turbinectomy.
  1. It avoided the vascular pedicle.
  2. Lower risk of hemorrhage.
  3. Studies on outcomes for partial turbinectomy vary.

Arbour P, and Kern EB. Paradoxical nasal obstruction. *Can J Otolaryngol* 4:333-338, 1975.

Fanous N. Anterior turbinectomy. A new surgical approach to turbinate hypertrophy: A review of 220 cases. *Arch Otolaryngology Head Neck Surg* 112:850-852,1986.

Wight RG, Jones AS, and Beckingham E. Radical trimming of the inferior turbinate and its effect on nasal resistance to airflow. *J Laryngol Otol* 102:694-696,1988.

# EXTRAMUCOSAL DESTRUCTION

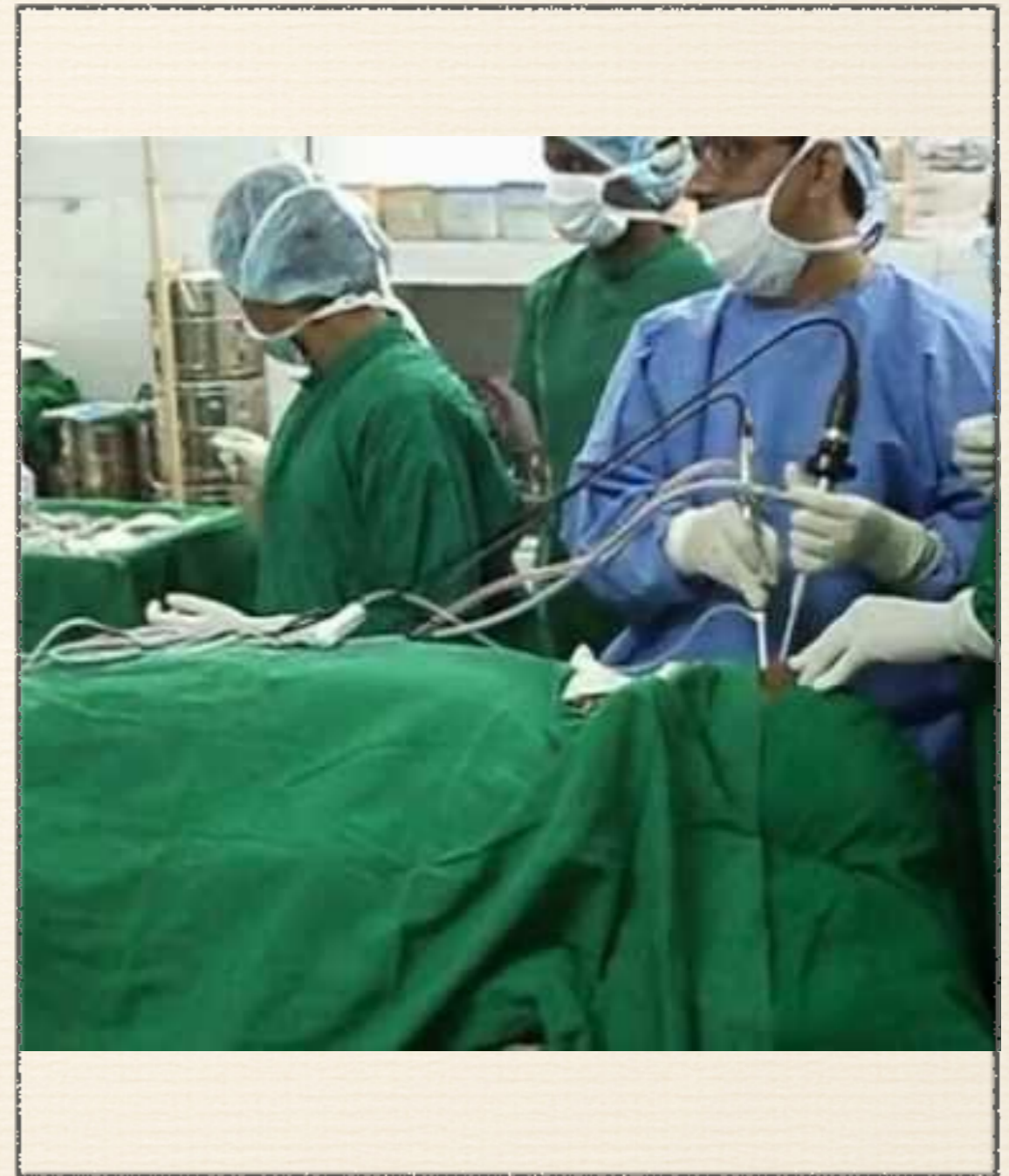- Lasers are used to perform a precise excision and/or ablation of hypertrophy turbinate tissue.
- The risk of hemorrhage is less.
- A study in 2007 by Sroka compared the Ho:YAG with diode lasers.
- Cryotherapy
  1. The critical temperature is  $-12^{\circ}\text{C}$ .
  2. Became less popular.

Elwany S, and Harrison R. Inferior turbineetomy: Comparison of four teehniques. J Laryngol Otol 104:206-209, 1990.

Sroka R, Janda P, Killian T, et al. Comparison of long term results after Ho:YAG and diode laser treatment of hyperplastic inferior nasal turbinâtes. Lasers Surg Med 39:324^331, 2007.

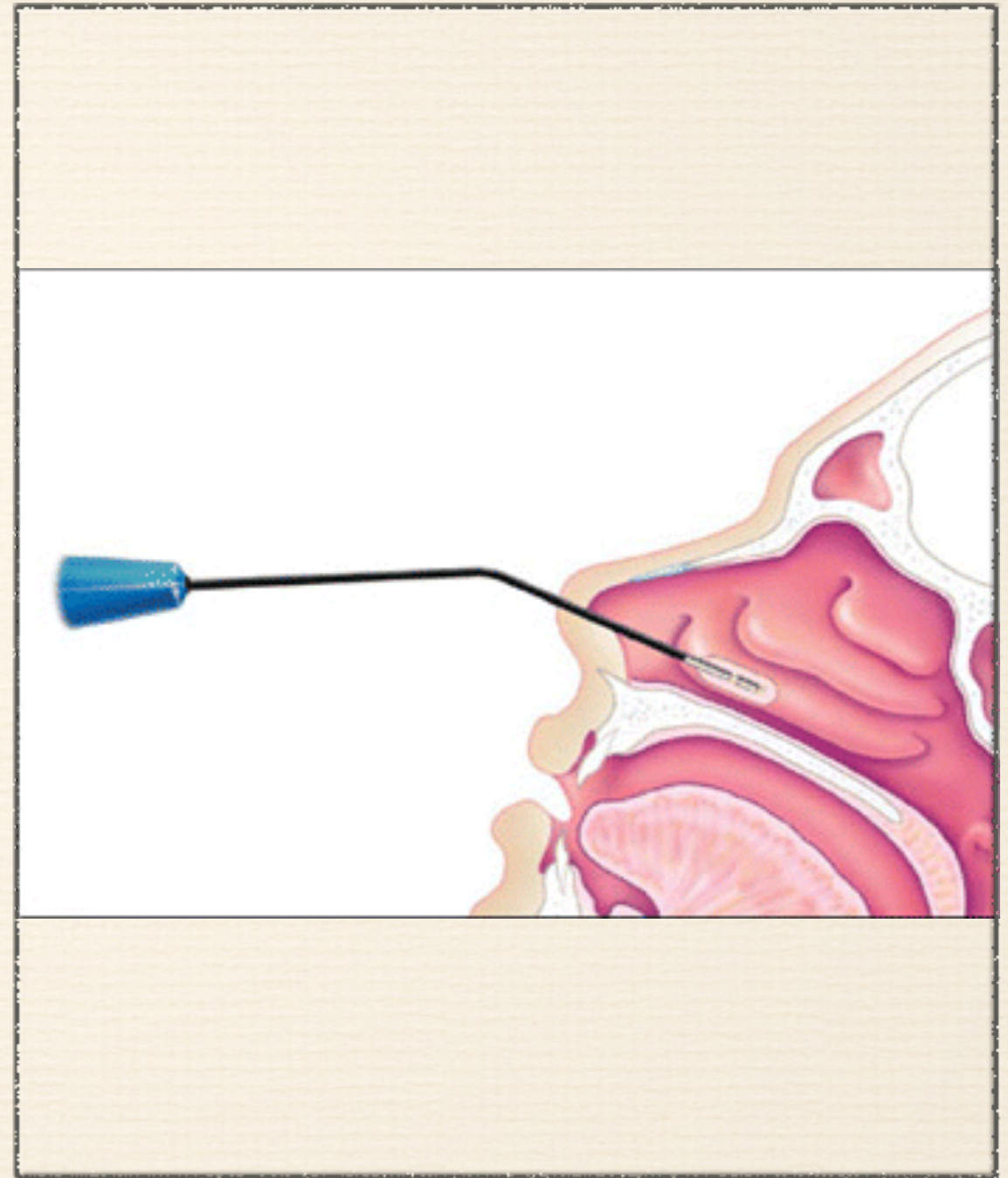
# SUBMUCOSAL LESION FORMATION AND TISSUE REMOVAL

- Most well-accepted surgical techniques for inferior turbinate reduction.
- Removal of submucosal tissue with or without bone removal.
- Without removal of the external mucosal layer.



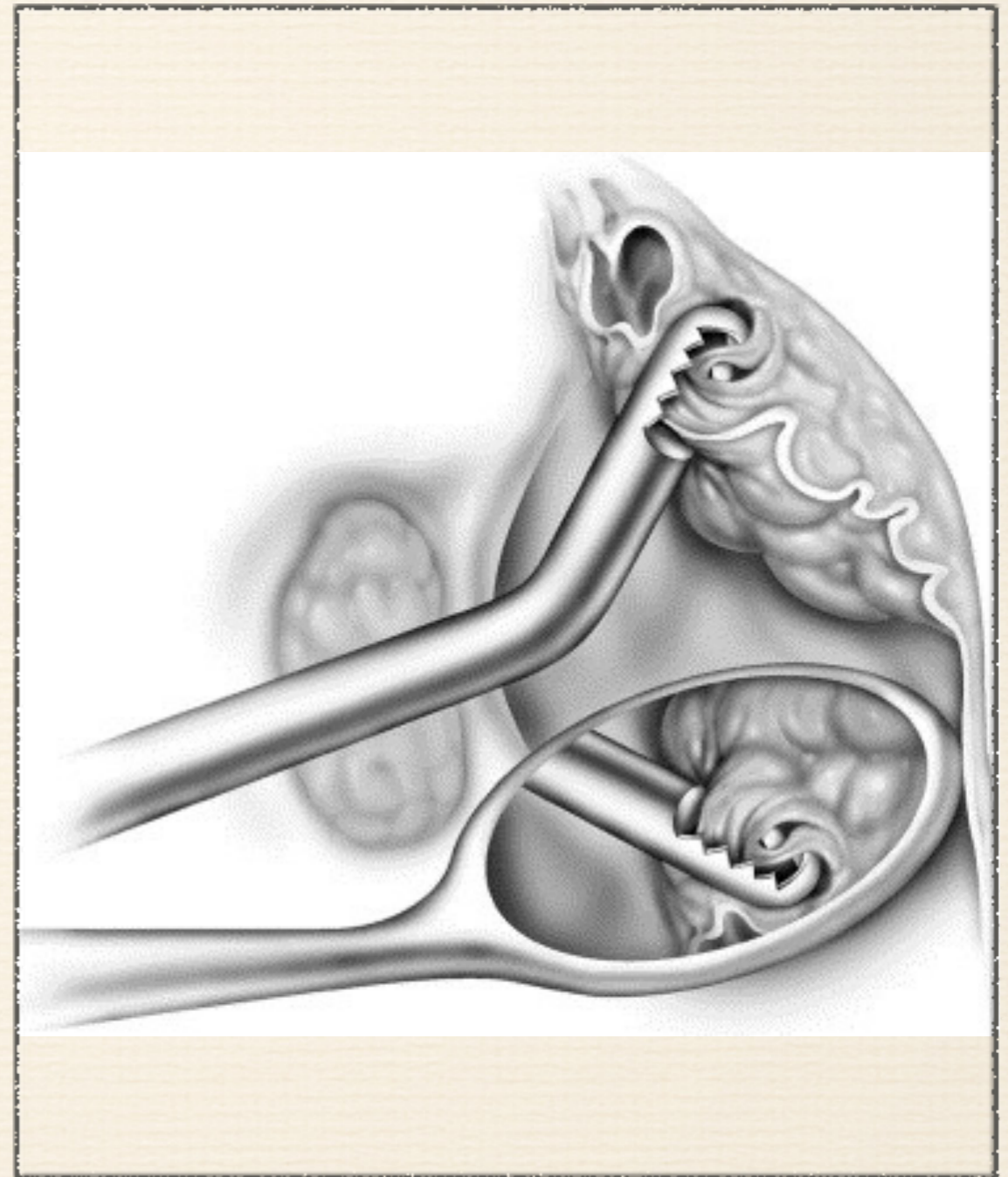
# RADIOFREQUENCY

- High tissue temperatures
- This is a simple and quick technique that can be performed in the office or operating room setting.
- Radio-frequency ablation using the Coblator.
- Maintains temperatures between 60 and 90°C.
- Bipolar Coblator and the monopolar somnoplasty.
- Well tolerated and provides favorable outcomes.



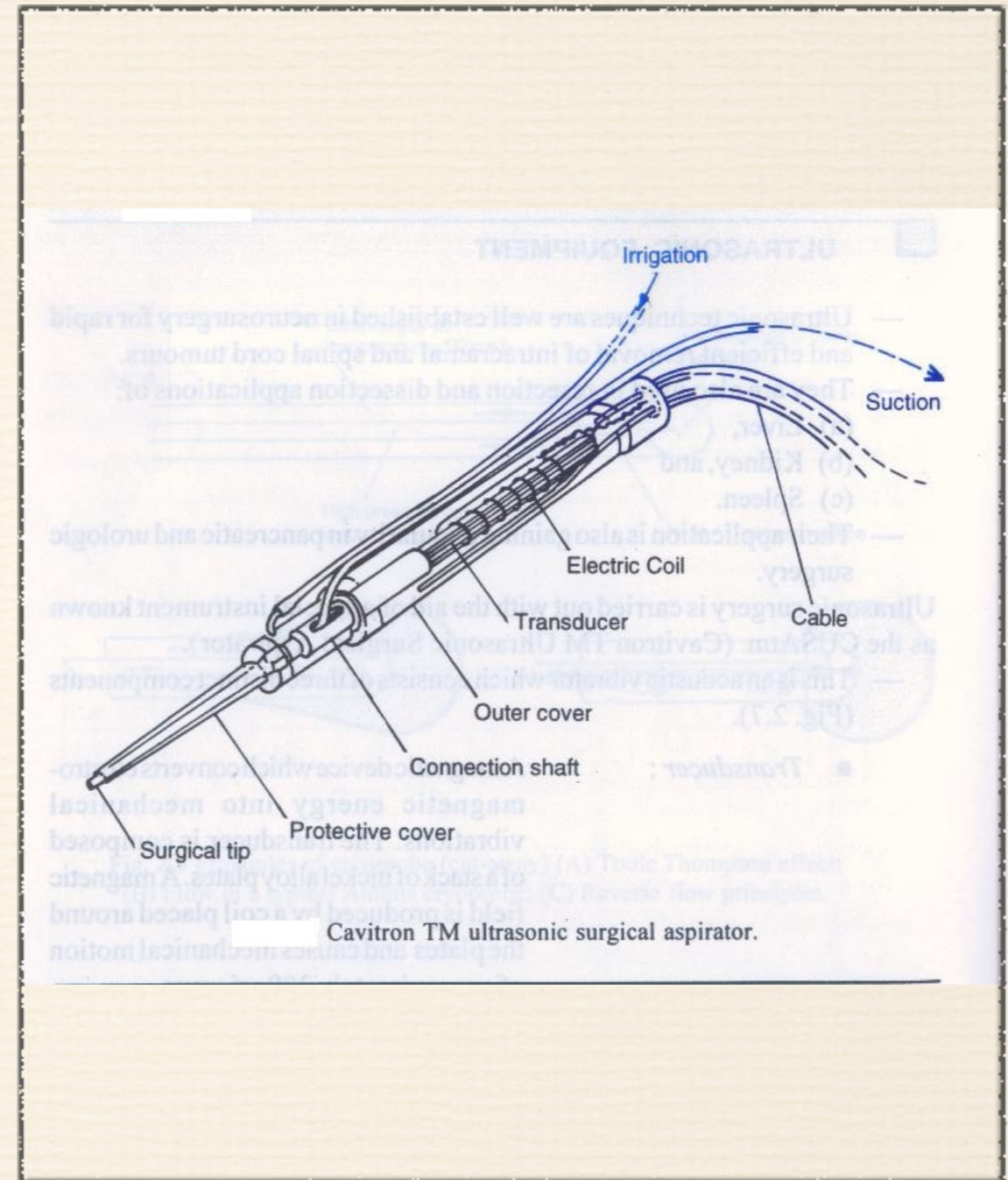
# MICRODEBRIDER

- Most commonly advocated.
- Complications are infrequent.
- Bipolar microdebrider technology
- Several potential advantages.



# ULTRASONIC ASPIRATOR

- Newest technique used in inferior turbinates surgery.
- The key feature of this instrument is tissue selectivity.
- Atraumatic to the surrounding soft tissue.
- Providing more control.
- The technique was first described by Greywood in 2010.
- Gindros compared ultrasonic aspiration to electrocautery and RFA.
- Ultrasonic turbinate reduction appears to be an effective and safe alternative.
- Needs more experience
- Expensive.



Greywoode JD, Van Abel K, and Pribitkin EA. Ultrasonic bone aspirator turbinoplasty: A novel approach for management of inferior turbinate hypertrophy. Laryngoscope 120(suppl 4):S239, 2010.

Gindros G, Kantas I, Balatsouras DG, et al. Comparison of ultrasound turbinate reduction, radiofrequency tissue ablation and submucosal eauterization in inferior turbinate hypertrophy. Eur Arch Otorhino-laryngol 267:1727-1733, 2010.

# COMPARATIVE EFFICACY

- The literature suggests that inferior turbinate surgery, regardless of the technique, is effective at improving nasal obstruction due to turbinate hypertrophy not responsive to medical therapy.
- Submucous microdebrider assisted and RFA techniques have been most studied.
- A randomized clinical trial by Passali in 2003.
- Significant improvement was noted initially in all groups.
- Patients with electro-cautery or cryotherapy had progressive worsening of nasal resistance.
- Laser cautery had reduced nasal volumes over the 6-year follow-up.
- Only the patients with submucosal resection achieved normal parameters for mucociliary transport time and secretory IgA concentration. The submucosal resection patients also experienced better quality of life scores.

- If all of the techniques described for managing ITH have established effectiveness, how does one decide which technique to use in any given patient? Should the same technique be used in every patient, every time?

Severity of ITH	Technique
Mild	Outfracture RFA (cautery/coblation)
Moderate to severe	SMR (microdebrider/other)
Massive/underlying disease	Extramural resection (partial)
Posterior tip hypertrophy	Extramural resection (microdebrider)

*Key: ensure accurate diagnosis and target pathology.  
May combine techniques, especially outfracture.  
ITH = inferior turbinate hypertrophy; RFA = radiofrequency ablation;  
SMR = submucous resection.*

# References

Bati-a PS, Seiden AM, and Smith TL. Surgical management of adult inferior turbinate hypertrophy: A systematic review of the evidence. *Laryngoscope* 119:1819-1827, 2009.

Eliashar R. Total inferior turbinectomy: Operative results and technique. *Ann Otol Rhinol Laryngol* 110:700, 2001.

Back LJ, Hytonen ML, Mahnberg HO, and YUkoski JS. Submucosal bipolar radiofrequency thermal ablation of inferior turbinates: A long-term follow-up with subjective and objective assessment. *Laryngoscope* 112:1806-1812, 2002.

Harrill WC, PiUsbury HC III, McGuirt WF, and Stewart MG. Radio-frequency turbinate reduction: A NOSE evaluation. *Laryngoscope* 117:1912-1919, 2007.

Joniau S, Wong I, Rajapaksa S, et al. Long-term comparison between submucosal cauterization and powered reduction of the inferior turbinates. *Laryngoscope* 116:1612-1616, 2006.

Gindros G, Kantas I, Balatsouras DG, et al. Comparison of ultrasound turbinate reduction, radiofrequency tissue ablation and submucosal cauterization in inferior turbinate hypertrophy. *Eur Arch Otorhinolaryngol* 267:1727-1733, 2010.

Sroka R, Janda P, Killian T, et al. Comparison of long term results after Ho:YAG and diode laser treatment of hyperplastic inferior nasal turbinates. *Lasers Surg Med* 39:324-331, 2007.

Breseovici S, and Roithmann R. Modified Glatzel mirror test reproducibility in the evaluation of nasal patency. *Braz J Otorhinolaryngol* 74:215-222, 2008.

Wolstenholme CR, Philpott CM, Oloto EJ, Murty GE. Does the use of the combined oral contraceptive pill cause changes in the nasal physiology in young women?. *Am J Rhinol*. Mar-Apr 2006;20(2):238-40.

Ozcan C, Vayisoglu Y, Dogu O, Görür K. The effect of intranasal injection of botulinum toxin A on the symptoms of vasomotor rhinitis. *Am J Otolaryngol*. Sep-Oct 2006;27(5):314-8.

Arbour P, and Kern EB. Paradoxical nasal obstruction. *Can J Otolaryngol* 4:333-338, 1975.

Famous N. Anterior turbinectomy. A new surgical approach to turbinate hypertrophy: A review of 220 cases. *Arch Otolaryngol Head Neck Surg* 112:850-852, 1986.

Wight RG, Jones AS, and Beckingham E. Radical trimming of the inferior turbinate and its effect on nasal resistance to airflow. *J Laryngol Otol* 102:694-696, 1988.

*Thank you*